

Therapeutic Management of Canine Skin Papillomatosis in Rajapalayam Native Dog Breed in Field Condition: A Case Study

Durairajan, R.¹ and J. Ramesh

Veterinary University Training and Research Centre, Tamil Nadu Veterinary and Animal Sciences University, Melmaruvathur-603 319, Tamil Nadu

(Received: October 2023 208/23 Accepted: June 2024)

Abstract

Three years old Rajapalayam she dog was presented with two small warts like growth on the surface of lower jaw since three months back. These growths were pure white in colour and were tentatively diagnosed as canine papillomatosis based on clinical examination. Treatment with thuja (a homeopathic medicine), anti-inflammatory and antibiotics was found to be effective in this case. Treatment with lithium antimony thiomalate showed promising results with sloughing of wart like growths in the affected dog.

Key words: Rajapalayam, she dog, papillomatosis, lithium antimony thiomalate

Papillomas or warts in dogs are benign growths caused by Papilloma viruses. Canine Papilloma viruses frequently affect the oral mucous membranes and skin of young and older dogs, respectively. Various methods available for treatment of canine papillomatosis are autogenous vaccine, surgical excision, cryotherapy, crushing of warts to stimulate immunity, apart from use of antibiotics like azithromycin, compounds like lithium antimony thiomalate (Dileepkumar and Ansari, 2012), vincristine sulphate, thuja (Nicolls and Stanley, 1999; Yaggci *et al.*, 2008; Singh and Bhardwaj, 2014) etc. This article describes the therapeutic management canine papillomatosis in Rajapalayam white color female dog in field condition.

Case History and Observations

A three years old Rajapalayam she dog was presented with two small warts like growth on

the surface of upper jaw since three months back. The dog was treated previously with antibiotics and anti-inflammatory drugs for five days with no improvement. Based upon clinical examination, size and shape of the warts the condition was diagnosed as papillomatosis.

Treatment with inj. lithium antimony thiomalate (Anthiomalin®; each ml contains 60 mg of lithium antimony thiomalate) was started with a total dose of 0.5 ml intramuscular (i.m) as first dose and second dose of 0.5ml given after two days interval. The third and fourth doses of the injection were given with a total dose of 1.5 ml in two days interval. Fifth and sixth doses of 2ml were given in two days interval. The dog showed fast recovery and there was complete regression of lesions after six doses of Anthiomalin. One of the lesion/warts like growth was fall down after third dose of injection. Another lesion was showing regression after final dose of the injection.

Treatment and Discussion

Papillomatosis contagious disease in dogs and livestock. Papillomas are usually small and do not adversely affect the health of the dog, but when they grow inwards into the mouth they cause discomfort, pain and interfere with chewing. Sometimes they may ulcerate and bleed. In severe cases, large areas may be involved and dogs so affected may not thrive. Application of an effective drug for treatment of is questionable. However, some drugs like Thuja occidentalis has been used (in human, dog and cattle) as topical application and/or subcutaneous injection, and other medicines such as azithromycin, cimetidine, etretinate, human recombinant interferon- α 2a, intramuscular

¹Corresponding author: Email: duraivet2006@gmail.com



Fig 1. At the first dose of the treatment showing papilloma in the upper Jaw

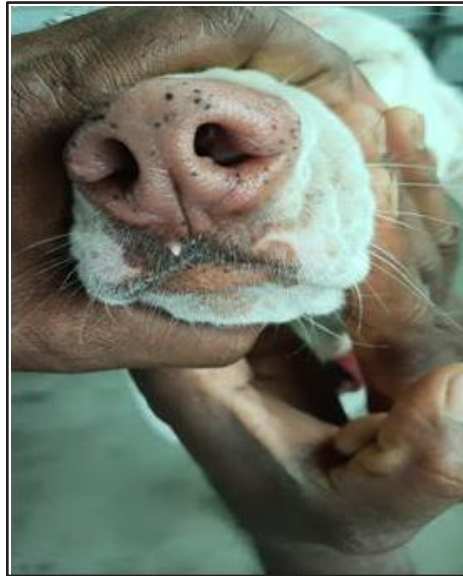


Fig 2. At third dose of the treatment showing one lesion fell down and another lesion of papilloma in the regression mode in the upper Jaw

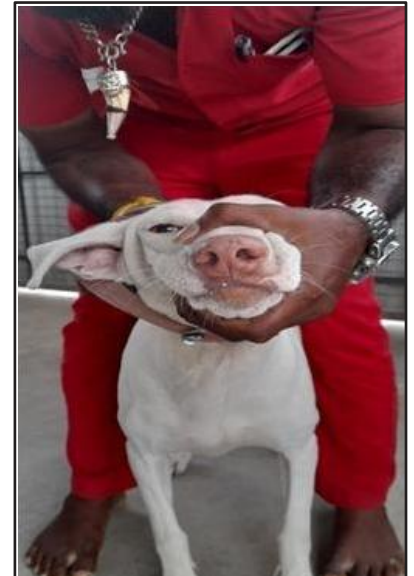


Fig 3. After, 6th dose complete regression of papillomatosis lesions

Propionibacterium acnes, intravenous tauridone and topical applications of 5- fluorouracil or imiquimod (Miller *et al.*, 2012; Umadevi and Umakanthan, 2013 and Punia *et al.*, 2021) have been tried for successful management of papillomatosis. The present case was treated with injection of lithium antimony thiomalate (Anthiomaline; each ml contains 60 mg of lithium antimony thiomalate) given intramuscularly at thigh region starting with a total dose of 0.5 ml, total six doses given at two days interval. After the final dose the dog showed improvement by regression of papillomatosis lesions. One of the lesions fell down during the 3rd dose of the injection. These findings were in accordance with the finding of Punia *et al.*, 2021 and they have used anthiomalin in alternate days with 0.5 ml dose as increment dose. This study also reports that white colored female Rajapalayam native breed of dogs are susceptible to papillomatosis in intensive system of rearing.

References

- Dileepkumar, K.M and Ansari, Md. M. (2012). Clinico-therapeutic management of cutaneous papillomatosis in a buffalo calf. *Intas Pol.* **13(1)**: 67-69.
- Miller, W.H., Griffin, C.E and Campbell, K.L. (2012). Viral Rickettsial, Protozoal Skin Diseases. In Muller and Kirk's Small Animal Dermatology. 7th ed. Philadelphia, 349.
- Nicholls, P.K and Stanley, M.A. (1999). Canine papillomavirus-A centenary review. *J. Com. Pathol.* **120**: 219-233
- Punia, S., Agnihotri, D., Tarun, K., Neelesh, S., Maneesh, S and Snehlata, C. (2021). Successful therapeutic management of canine oral papillomatosis. *The Pha. Inn. J.* **10(11)**: 2169-2171
- Singh, J and Bhardwaj, Y (2014). Clinical management of oral papillomas in a dog. *Intas Pol.* **15(1)**: 34-35.
- Umadevi, U and Umakanthan, T. (2013). Successful combined drug therapy for the treatment of papilloma in cattle. *In. J. Bio. Pha. Sci.* **4**: 657-658.
- Yagci, B.B., Ural, K., Ocal, N and Haydardedeoglu, A.E. (2008). Azithromycin therapy of papillomatosis in dogs: a prospective, randomized, double-blinded, placebo-controlled clinical trial. *Vet. Derma.* **19(4)**: 194-198.