

## Septic Arthritis associated with Actinomycosis in a Kid – A Case Report

Karthika, K., R.Jothipriya, M.Saravanan, E.Tamileniyan and M.Jeevitha

Veterinary College and Research Institute, Orathanadu – 614625

\*Email: karthika1988.6@gmail.com

Received: July 2024

142/24

Accepted: December 2024

### ABSTRACT

A one-month-old kid was presented with the history of lameness, swelling in all the joints and complete anorexia for the past 3 days. The clinical examination revealed an enlarged lymph node, an elevated rectal temperature (39.6 °C), and soft swelling in the joints of all limbs. Based on the history and clinical findings, the case was diagnosed as Septic arthritis associated with actinomycosis. The treatment was done with anti-microbial therapy, Amikacin @15mg/kg, NSAID Meloxicam @0.5mg/kg, with supportive care. The animal showed complete recovery after 10 days of treatment.

**Keywords:** Kid, Septic arthritis, Actinomycosis, Joint-ill, Amikacin

### INTRODUCTION

The major cause of economic loss in goat rearing is the mortality of kids before weaning (Ajoy *et al.*, 2022). Lack of proper management after parturition causes joint ill and navel ill. Arthritis in kids can be infectious or non-infectious. Infectious arthritis is widely seen as a consequence of bacteraemia. This paper deals with the septic arthritis associated with actinomycosis and its therapeutic management.

### CASE HISTORY AND OBSERVATION

A one-month-old non-descript female kid was presented to the Large Animal Medicine Unit of Veterinary Clinical Complex, Veterinary College and Research Institute, Orathanadu, with a history of swelling in all the joints (Fig. 1) and anorexia in the last three days. Clinical examination revealed an enlarged lymph node, elevated rectal temperature (39.6°C) with soft swelling in the joints of all limbs. On aspiration, serosanguinous fluid emerged,

which was subjected to microbiological and cytological analysis. Cytological examination of the fluid revealed suppurative inflammation associated with bacteria. The fluid was subjected to Gram staining, which confirmed the presence of *Actinomyces* sp., characterized by purple-coloured bacilli (Fig. 2) and further confirmed by culture.

### TREATMENT AND DISCUSSION

The animal was initially treated with Inj. Streptopenicillin @20,000IU/kg against the infection, where the clinical signs persisted the next morning. Antibiotic therapy was changed based on ABST to Inj. Amikacin @15mg/kg B.W. I/M for 7 days. In addition, the animal was treated with Inj. Meloxicam @0.5mg/kg B.W. I/M, Inj. Chlorphenamine maleate @0.5mg/kg B.W. I/M and Inj. Vit B<sub>1</sub>, B<sub>6</sub>, B<sub>12</sub> @1ml I/M for the following consecutive days. The kid showed recovery after 10 days of treatment.

*Mycoplasma mycoides* subsp. *mycoides*, *Trueperella pyogenes*, *Staphylococci*, *Streptococci*, *Corynebacterium* spp., *Actinomyces* spp., *Erysipelothrix rhusiopathiae*, and *Escherichia coli* are the bacteria incriminated to cause septicemic-arthritis syndrome in goats (Thomson, 2007). Actinomycetes are Gram-positive, non-acid-fast, polymorphic, slow-growing bacteria that cause pyogranulomatous lesions (Radostits and Done, 2007). This case showed a lesion in the joint region. *Actinomyces pyogenes* is a widespread cause of animal diseases, notably summer mastitis, endometritis, liver and foot abscesses, endocarditis, chronic nonsuppurative pneumonia, and suppurative arthritis, especially among sheep, Goat and cattle (Carter *et al.*, 1995). Since they are common in ruminants that can spread by the

haematogenous route, they arise due to abrasions in the oral/gastrointestinal mucosa or dental disorders, leading to joint infection. In order to be effective, therapy must begin instantaneously, and antibiotic selection should be based on bacteriologic culture and antimicrobial susceptibility tests. The cause of bacteraemia should also be identified and eliminated. The recommended preventive measure is to maintain adequate sanitation in the goat dwelling. Further research is required to confirm the *Actinomyces* spp., by molecular tests like PCR.

#### ACKNOWLEDGEMENT

The authors thank the Dean and the Professor and Head, Veterinary Clinical Complex, Veterinary College and Research Institute, Orathanadu, for their support.

#### REFERENCES

- Ajoy, D., D.Asish, R.Saroj, K.Muthupalani and K.M.Dilip (2022), Strategies for reduction of kid mortality in goats, *Indian Farming*, **72**(06): 17-21.
- Carter, G.R., M.M.Chengappa and A.W.Roberts (1995). *Essentials of Veterinary Microbiology*, 5<sup>th</sup> Ed. Baltimore, MD, USA, William and Wilkins, p. 214-216.
- Radostits, O. M. and S.Done (2007), *Veterinary Medicine: A textbook of diseases of cattle, horses, sheep, pigs and goats*, Diseases caused by *Actinomyces* spp., Edinburgh, Saunders Elsevier, p. 1045-1046.
- Thomson, K. (2007), *Bones and joints*, In: Jubb, Kennedy and Palmer's *Pathology of Domestic Animals*, Vol. 1, 5<sup>th</sup>Ed., USA, Saunders Ltd., p. 2-180.

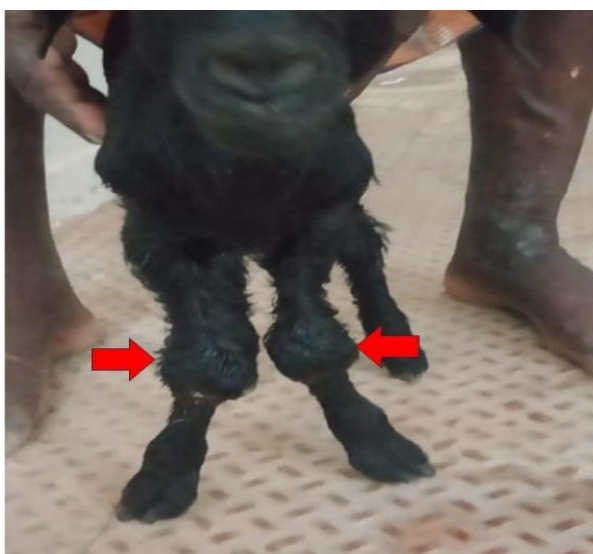

Fig. 1: Kid presented with swelling in joints

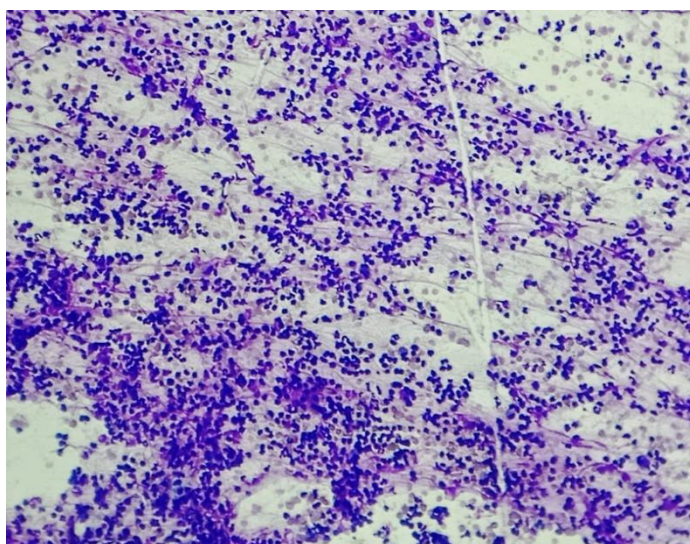


Fig. 2: Gram-positive bacilli noticed in aspirated fluid