

Prednisolone-induced Cholelithiasis in a Siberian Husky Dog

Lekshmi, M.R.*, Biju P.Habeeb, N.Madhavan Unny, P.Vinu David, P.T.Dinesh and A.Janus

Department of Veterinary Clinical Medicine, Ethics and Jurisprudence, College of Veterinary and Animal Sciences, KVASU, Pookode, Wayanad-673 576

*Email: lekshnimadhuram@gmail.com

Received: August 2024

176/24

Accepted: December 2024

ABSTRACT

A one-year-old male Siberian Husky dog affected with mixed species of *Babesia gibsoni* and *Babesia canisvogeli* infection developed cholelithiasis after prednisolone therapy. Initially, gallbladder sludge was observed on hepatic ultrasonography, which progressed into cholelith during the course of treatment. Upon discontinuation of steroid therapy and the inclusion of ursodeoxycholic acid and taurine supplements in the treatment regimen, a significant reduction in the size of the cholelith was observed.

Keywords: Prednisolone, cholelithiasis, ursodeoxycholic acid

Choleliths or gall stones are calculi that are formed due to bile precipitation, commonly within the gall bladder and infrequently in the intrahepatic or extrahepatic bile ducts (Larson, 2016). Factors such as gall bladder inflammation, mucin hypersecretion, cellular debris, bilirubin deconjugation and biliary stasis served as the nidus for the development of these choleliths (Mehler and Bennett, 2006). Prednisolone administration has been shown to reduce gall bladder emptying rate in dogs, predisposing them to biliary stasis (Nagahara *et al.*, 2018). Cholelithiasis was commonly observed in middle-aged to older small-breed dogs and is usually asymptomatic (Kanemoto *et al.*, 2017), but it can lead to complications such as extrahepatic biliary tract obstruction, cholecystitis, gall bladder perforation or rupture, if left untreated (Ward *et al.*, 2020). Symptomatic cholelithiasis in dogs can be manifested as vomiting, anorexia,

weakness, polyuria, polydipsia, weight loss, icterus, fever, and abdominal pain. In dogs, choleliths are predominantly pigment stones composed of calcium carbonate and bilirubin pigments (Center, 2009). Ultrasonography is the preferred diagnostic imaging method for hepatobiliary diseases in dogs with choleliths, appearing as mobile hyperechoic structures that produce distal acoustic shadowing (Larson, 2016). While surgical management is common, ursodeoxycholic acid has been successfully used for the resolution of cholelithiasis in dogs (Allan *et al.*, 2020). This synthetic hydrophilic bile acid reduces cell and oxidative damage due to bile acid retention in the liver by stimulating bile flow and displacing hydrophobic bile acids (Bexfield and Watson, 2009). This case report discusses the occurrence of prednisolone-induced cholelithiasis during the treatment period of mixed species babesia infection in a Siberian Husky dog.

CASE HISTORY AND OBSERVATION

A one-year-old male Siberian Husky dog weighing 16.8kg was brought to the Teaching Veterinary Clinical Complex, Pookode, with the complaint of hyporexia and icterus and was diagnosed as infected with mixed species babesia infection (*Babesia gibsoni* and *Babesia canisvogeli*), based on blood smear examination and PCR test. Hematobiochemical findings on the day of presentation indicated hyperbilirubinemia, elevated levels of alkaline phosphatase, gamma-glutamyl transferase and alanine aminotransferase with regenerative anaemia and thrombocytopenia (Tables I and II).

Organomegaly and pain in the cranial part of the abdomen were observed on palpation. Ultrasonography on the day of presentation revealed hyperechoic hepatic parenchyma with hepatomegaly, gall bladder wall thickness of 2.25 mm, hypoechoic gravity-dependent sludge in the gall bladder lumen with a normal volume of 0.53mL/kg (calculated using the ellipsoid equation, volume = 0.53 x L x H x W) (Atalanet *al.*, 2007). Treatment was initiated with Clindamycin @ 25mg/kg PO q12h, Metronidazole @ 15mg/kg PO q12h and Doxycycline @ 5mg/kg PO q 12h, along with prednisolone (1 mg/kg PO q 24hr for 7 days, then tapered) for correcting thrombocytopenia for 14 days. Even though the animal showed a good response to treatment on the 14th day, ultrasonography revealed an increase in gall bladder wall

thickness of 3.05mm, suggestive of cholecystitis, with hypoechoic immobile sludge throughout the lumen and an increased gall bladder volume of 1.61mL/kg. Despite a negative blood smear result on the 28th day of treatment, ultrasonography review showed the progress of the previously immobile sludge in the gall bladder into a hyperechoic cholelith, casting a distal acoustic shadow surrounded by anechoic bile. Gall bladder wall thickness was 1.32mm and volume 0.61mL/kg. The animal showed no clinical signs of cholelithiasis except for mild pain on abdominal palpation. Detailed findings from ultrasonography are listed in Table III. Based on the ultrasonographic findings and the history of prednisolone therapy, the case was diagnosed as prednisolone-induced cholelithiasis.

Table I: Haematological Findings

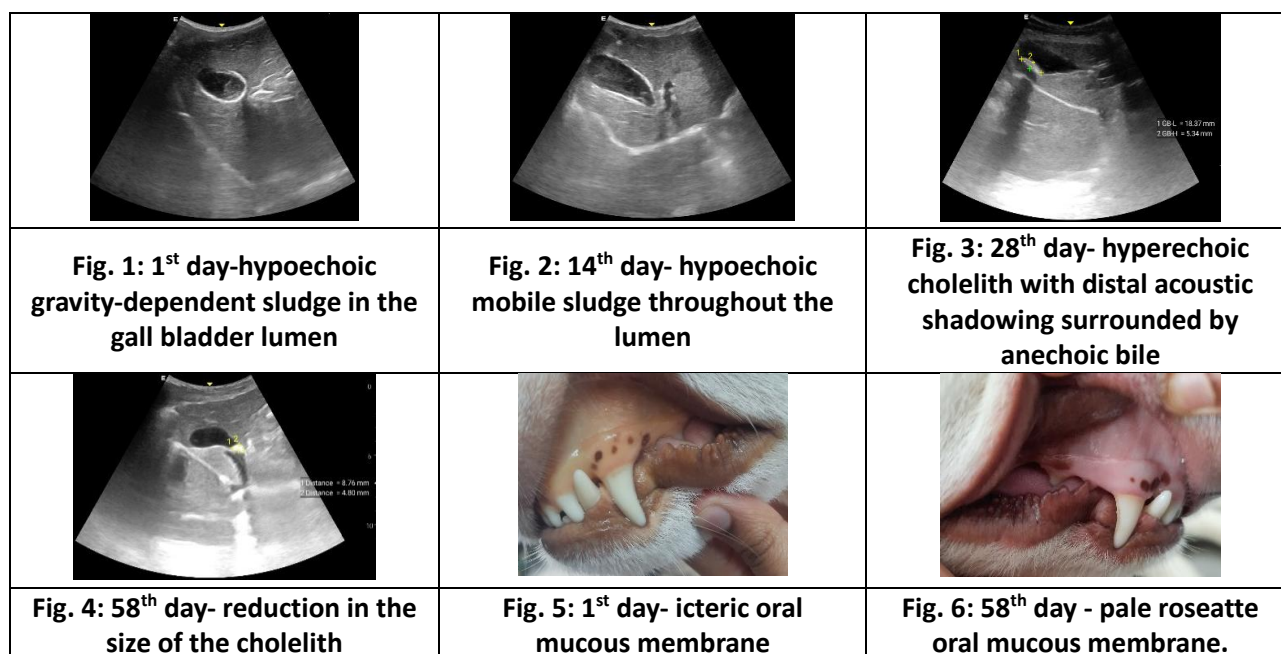
Haematology	1 st Day	14 th Day	28 th Day	58 th Day
RBC (10 ⁶ /μL)	1.68	3.50	4.65	5.06
WBC (10 ³ /μL)	13.57	10.40	7.83	11.16
Hg (g/dL)	4.60	9.90	12.30	12.30
VPRC (%)	14.50	31.70	37.50	37.50
Thrombocyte count (10 ³ /mm ³)	33.00	79.00	133.00	166.00

Table II: Serum Biochemistry Values

Serum Biochemistry	1 st Day	14 th Day	28 th Day	58 th Day
Total bilirubin (mg/dL)	9.64	0.84	0.30	0.26
Direct bilirubin (mg/dL)	7.81	0.51	0.23	0.06
Total protein (g/dL)	5.54	5.11	4.66	4.51
Albumin (g/dL)	2.28	2.84	2.48	2.29
Globulin (g/dL)	3.26	2.27	2.18	2.22
ALP (IU/L)	1,171.40	1,215.50	314.30	171.30
GGT (IU/L)	22.25	56.42	13.08	6.87
ALT (IU/L)	364.71	306.12	102.02	34.76
Cholesterol (mg/dL)	169.10	205.37	154.72	138.23
Glucose (mg/dL)	105.00	72.14	72.00	78.00

Table III: Ultrasonographic Findings

USG Findings	1 st Day	14 th Day	28 th Day	58 th Day
Gall bladder wall thickness (mm)	2.25	3.05	1.32	0.95
Echogenicity of gall bladder contents	Hypoechoic gravity-dependent sludge	Hypoechoic sludge throughout the lumen	Cholelith l=18.37 mm, h=5.34 mm, with distal acoustic shadowing	Cholelith l=8.76 mm, h=4.80 mm, with distal acoustic shadowing
Mobility of gall bladder contents	Mobile	Mobile	Mobile	Mobile
Gall bladder volume (mL/Kg)	0.53	1.61	0.61	0.21
Hepatic size	Enlarged	Enlarged	Normal	Normal
Hepatic echogenicity	Hyperechoic	Hyperechoic	Hyperechoic	Hyperechoic



TREATMENT AND DISCUSSION

Due to the development of cholelith, steroid therapy was discontinued on the 28th day and the dog was given ursodeoxycholic acid (15 mg/kg orally once daily), S-adenosyl methionine (20mg/kg orally once daily before food), along with silymarin and taurine supplements. Taurine is essential for bile acid conjugation and prevents bile acid precipitation (Johnson and Sherding, 2006).

On the 58th day of treatment, a reduction in the size of the cholelith was evident along with decreased levels of serum total bilirubin, ALP, GGT and ALT values. Similar improvements in cholelithiasis were reported by Allan *et al.* (2021) in dogs treated with ursodeoxycholic acid. Kanemoto *et al.* (2017) also reported a similar case of cholelithiasis without typical clinical signs. Cholecystitis characterized by gall bladder wall thickening of more than 2 mm (Barrett, 2020), was observed in this case

on the first day and 14th day of treatment. This thickening reduced to 0.95mm on the 58th day in response to the treatment. Yogeshpriya *et al.* (2017) reported a similar resolution of concurrent cholecystitis in a dog with *Babesia gibsoni* infection. On the 14th day of steroid therapy, the gall bladder volume increased to 1.16mL/kg, exceeding the normal value of less than or equal to 1ml/kg (Ramstedt *et al.*, 2008). Following steroid withdrawal and introduction of ursodeoxycholic acid, the gall bladder volume reduced to 0.21mL/kg. Prednisolone administration is known to decrease gall bladder emptying rate in dogs (Nagahara *et al.*, 2018) which may lead to cholestasis and serve as a nidus for the development of cholelith. Yarimagan and Bor (1986) reported that the lithogenicity of bile was increased in animals receiving methylprednisolone. These factors might have contributed to the formation of cholelith in this case. Ursodeoxycholic acid modified the toxic bile acid pool through its choleric effect and reduced hepatic synthesis and secretion of cholesterol, resulting in the resolution of the cholelith. This study stresses the need for monitoring of animals during their indicated prednisolone therapy.

SUMMARY

Ultrasonographic evaluation was useful to assess the progress of cholelithiasis and its response to treatment in a dog. Ursodeoxycholic acid and taurine were effective in managing prednisolone-induced cholelithiasis in a Siberian Husky dog.

REFERENCES

- Allan, F., McCallum, K.E., Genain, M.A., Harris, B.J. and Watson, P.J. (2020). Dissolution of cholelithiasis in a Cavalier King Charles Spaniel receiving conservative management with ursodeoxycholic acid. *Vet. Rec. Case Reports.* **8**(3): e001206.
- Allan, F., Watson, P.J. and McCallum, K.E. (2021) Clinical features and outcomes in 38 dogs with cholelithiasis receiving conservative or surgical management. *J. Vet. Intern Med.* **35**(6): 2730-2742.
- Atalan, Gultekin, Barr, F.J. and Holt, P.E. (2007) Estimation of the volume of the gall bladder of 32 dogs from linear ultrasonographic measurements. *Vet. Rec.* **160**(4): 118-122.
- Barrett, E. (2020) Imaging in hepatobiliary disease. *Clinical Small Animal Internal Medicine.* 659-675.
- Bexfield, N. and Watson, P. (2009) Treatment of canine liver disease: 1. drugs and dietary management. *In practice.* **31**(3): 130-135.
- Center, S.A. (2009). Diseases of the gallbladder and biliary tree. *Vet. Clin. Small Anim. Pract.* **39**(3): 543-598.
- Johnson, S.E. and Sherding, R.G. (2006) Diseases of the liver and biliary tract. *Saunders manual of small animal practice* (3rd edition), St. Louis, Missouri, 747.
- Kanemoto, H., Fukushima, K., Tsujimoto, H. and Ohno, K. (2017) Intrahepatic cholelithiasis in dogs and cats: a case series. *Can. Vet. J.* **58**(9). 971.
- Larson, M.M. (2016) Ultrasound imaging of the hepatobiliary system and pancreas. *Vet Clin North Am Small Anim Pract.* **46**(3): 453-80.
- Mehler, S.J. and Bennett, R.A. (2006) Canine extrahepatic biliary tract disease and surgery. *Compend. Contin. Educ. Pract. Vet.* **28**(4): 302.
- Nagahara, T., Ohno, K., Kanemoto, H., Kakimoto, T., Fukushima, K., Goto-Koshino, Y. and Tsujimoto, H. (2018) Effect of prednisolone administration on gallbladder emptying rate and gallbladder bile composition in dogs. *Am. J. Vet. Res.* **79**(10): 1050-1056.
- Ramstedt, K.L., Center, S.A., Randolph, J.F., Yeager, A.E., Erb, H.N. and Warner, K.L. (2008) Changes in gallbladder volume in healthy dogs after food was withheld for 12 hours followed by ingestion of a meal or a meal containing erythromycin. *Am. J. Vet. Res.* **69**(5): 647-651.
- Ward, P.M., Brown, K., Hammond, G., Parkin, T., Bouyssou, S., Coia, M., Nurra, G. and Ridyad, A.E. (2020) Cholelithiasis in the dog: prevalence, clinical presentation, and outcome. *J. Am. Anim. Hosp. Ass.* **56**(3): 152.
- Yarimagan, H.S. and Bor, N.M. (1986) Changes of bile lipid composition induced by methylprednisolone. *Biochem. Med. Metabolic Biol.* **35**(1): 7-11.
- Yogeshpriya, S., Selvaraj, P., Sivakumar, M., Venkatesan, M. and Veeraselvam, M. (2017) Intravenous clindamycin in the management of *babesia gibsoni* in a labrador with concurrent cholecystitis. *Indian J. Vet. Med.* **37**(1&2): 80-81.

