

Gross Biometrical Analysis of the Sternum of Indigenous Poultry of Poonch Region of Jammu and Kashmir

Jasvinder Singh Sasan*, Shalini Suri and Kamal Sarma

Division of Veterinary Anatomy, Faculty of Veterinary Science and Animal Husbandry, SKUAST, Jammu

Email: jssasan216@gmail.com

Received: June 2024

132/24

Accepted: January 2025

ABSTRACT

The present study was conducted on the sternum (N=06) of indigenous poultry of Poonch region. The sternum is the major supportive element within the ventral body wall. The body of the sternum was elongated, concave dorsally and convex ventrally for attachment to breast muscles. The cranio-lateral process was elongated and directed cranially. The caudo-lateral process started as a single process, which bifurcated into a smaller dorsal and a longer ventral process, both directed caudally. The caudo-dorsal process was much wider at its terminal end than the caudo-ventral process. Two lateral pneumatic foramina were located on either side of mid-line towards the cranial end of the body, whereas the median pneumatic foramen was absent. The cranial border of the sternum presented transversely elongated grooves separated by a rostrum to articulate with the distal extremity of the coracoid bone just below the cranial border. Anteriorly, the lateral border presented four facets for the sternal ribs. The rostrum was a quadrilateral plate-like in outline. The ventral surface presented triangular shaped keel (carina) in the midline. The cranial border was concave, and the apex was in level as the origin of the caudo-lateral process. Length of sternum was 13.36 ± 0.093 cm. The width of the sternum was maximum at the level of facets (3.27 ± 0.051 cm). The cranio-lateral processes were the shortest, and the caudo-ventral processes were the longest. The height of the keel was maximum at its apex.

Keywords: Biometry, Keel, Sternum, Pneumatic foramen, Poonch

INTRODUCTION

The Union Territory of Jammu and Kashmir belongs to the greater Himalayan mountain range, which exerts significant influence on its agro-climatic conditions. District Poonch has a humid, subtropical climate, which is much cooler than the rest of India due to its moderately high elevation and northerly position. Indigenous poultry rearing provides sustainability to the local people. The indigenous poultry of the Poonch region weighs about 2.1-2.5 kg (cock) and 1.6-1.8 kg (hen). Females are combless, whereas males present red coloured comb and can survive well in 0° C temperature.

The avian skeleton is highly adapted for flight characterized by a prominent sternum, pelvis that is opened ventrally, forelimb modified to a wing and fusion of vertebrae (Dyce *et al.*, 2010). The sternum is an extensive bone that forms the floor of the thoracic cavity and part of the abdominal cavity of fowl (Pathak *et al.*, 2017). The sternum plays an important role in the flight mechanism as it provides an attachment area for the pectoralis and supra-coracoideus muscles having function in wing flapping (Altshuler *et al.*, 2015). Sternal crest is most developed in sophisticated fliers like swifts and hummingbirds and least developed in the flightless ratites, which have a flat and raft-like sternum (Bezuidenhout, 1999). The morphological variation, depending upon the species, may exist in the development of keel,

processes, sternal spine and in the presence or absence of pneumatic foramen (John *et al.*, 2014a).

Literature is available on the gross anatomy and biometry of sternum of avian species (Duzler *et al.*, 2006), pigeon, crow and owl (John *et al.*, 2014b), emu, turkey and duck (Jayachitra *et al.*, 2015), peacock, turkey, duck and waterhen (Pathak *et al.*, 2017), moorhen (Wani *et al.*, 2017), Japanese domestic fowls (Kudo *et al.*, 2017), owl (Choudhary *et al.*, 2018), crow (Sunilkumar *et al.*, 2019), crane (Girgriet *et al.*, 2022), domestic fowl (Jones *et al.*, 2023). An anatomical study has been carried out on organs like the gizzard of the indigenous poultry (Sasan *et al.*, 2023), but no information is available on the sternum. There is a positive correlation between flight capability and the height of the sternal crest to which flight muscles insert (Dursun *et al.*, 2002). Keeping in view the functional aspect of the sternum, the present study was planned to focus on the gross morphology and biometry of the sternum in this indigenous poultry.

MATERIALS AND METHODS

The present study was conducted on the sternum of indigenous poultry of the Poonch region. Carcasses of six birds were obtained from the Division of Animal Genetics and Breeding, F.V.Sc. & A.H., SKUAST-Jammu. Immediately after collection, the bones were processed as per the standard techniques (Raghavan, 1964) and used for recording various morphological characteristics and biometrical parameters.

RESULTS AND DISCUSSION

Gross morphology

The sternum forms a major supportive element along the ventral body wall, and its shape varies with species (Konig *et al.*, 2016). It was located on the antero-ventral aspect of the body cavity

and gave attachment to the coracoid and sternal ribs (Jayachitra *et al.*, 2015). The dorsal aspect of the sternum was roughly pyramidal with base cranially and apex directed caudally, which was similar to the findings of Wani *et al.* (2017) in moorhen. Wani *et al.* (2018) in a crow divided the sternum into three parts, i.e. body, rostrum and keel and divided the body of the sternum of the moorhen into anterior and posterior parts with the origin of the caudo-lateral process as a demarcation point.

The body was elongated, concave dorsally and convex ventrally, which gives attachment to breast muscles (Jayachitra *et al.*, 2015). A roughly quadrilateral body was observed in peacock and turkey (Pathak *et al.*, 2017) and crow (Wani *et al.*, 2018). The cranio-lateral process was elongated and directed cranially (Fig. 1) and represented the limit of the cranial opening of the ribcage (Konig *et al.*, 2016). This process extended up to the rostrum, unlike in the peacock, where this process did not extend up to the rostrum (Pathak *et al.*, 2017). The process was highly developed in owl, moderately in crow and highly reduced in pigeon (John *et al.*, 2014a). The caudo-lateral process started as a single process that bifurcated into a smaller dorsal and a longer ventral process, both directed caudally (Fig. 1). The caudo-dorsal process was much wider at its terminal end than the caudo-ventral process. The caudo-ventral process and lateral border of the body delineate the medial incisure, whereas the dorsal and ventral processes form the boundary of the lateral incisure. In a live bird, both these incisures were closed by connective tissue membranes (Konig *et al.*, 2016). The caudo-lateral process was absent in the emu (Jagapathi *et al.*, 2007).

In the present study, the median pneumatic foramen was absent, but two lateral pneumatic foramina were located on either side of the midline towards the cranial end of the body (Fig.

2). This was similar to the findings of Pathak *et al.* (2017) in the white-breasted water hen. Sunilkumar *et al.* (2019) in the crow reported several pneumatic foramina arranged linearly in the midline for communication with air sacs. In ducks, there was only a single foramen located at the cranial border of the midline of the basal plate (Sumena and Lucy, 2015). Pneumatization is derived from diverticulae originating from the clavicular air sac (Konig *et al.*, 2016).

Cranial border was thick, convex and triangular in outline (Fig. 2), as reported by Tomar *et al.* (2011) in the pariah kite. It presented a transversely elongated groove to articulate with the distal extremity of the coracoid bone just below the cranial border (Fig. 3). This acts as a base for the shoulder (Yasuda, 2002). The groove was bordered by a dorsal and ventral lip as observed by Choudhary *et al.* (2018) in the owl. Grooves were separated by a plate-like rostrum in the middle (Fig. 3). The caudal border was in the form of a pointed projection. Anteriorly, the lateral border was thick and present four facets for sternal ribs (Fig. 2). These facets were located between the origin of cranio-lateral and caudo-lateral processes. The lateral border on either side presented four articular facets in black drongo (Sumena and Lucy, 2015), peacock and turkey (Pathak *et al.*, 2017), five facets in owl (Choudhary *et al.*, 2018) and crow (Sunilkumar *et al.*, 2019), six facets in duck (Sumena and Lucy, 2015), seven in Black-crowned crane (Girgiri *et al.*, 2022). Posteriorly, the lateral border was concave, similar to the findings of Wani *et al.* (2018) in the crow.

Rostrum was plate-like quadrilateral in outline (Fig. 4), similar to the findings of Pathak *et al.* (2017) in peacock and Sathyamoorthy *et al.* (2006) in Asian koel. However, the rostrum was typically Y-shaped in the crow (John *et al.*, 2018) and hook-shaped in green winged macaw (Sreeranjini *et al.*, 2015). The sternum of the pariah kite was devoid of a rostrum (Tomar *et*

al., 2011). Choudhary *et al.* (2018) reported triangular shaped rostrum in an owl.

The ventral surface was convex and presented triangular shaped keel (carina) in the midline (Fig. 4) as reported by Sunilkumar *et al.* (2019) in the crow. The sternum of the ostrich was devoid of a keel (Sathyamoorthy and Ramesh, 2006). The height of the keel was maximum cranially, which decreased caudally. The cranial border was concave and the apex was in level as the origin of the caudo-lateral process. However, in the black drongo, the apex was in level as the manubrium (Sumena and Lucy, 2015). The dorsal border fused with the ventral surface of the body of the sternum, whereas the ventral border was convex. In the crow, the ventral border of the keel bifurcated caudally, and each ridge joined the caudo-lateral angles of the body of the sternum. The height of the keel alone should not be considered as the index for flying abilities because in chickens, the keel is deep, but it is a poor flier (Dyce *et al.*, 2010).

Biometry

The length of sternum was 13.36 ± 0.093 cm which was longer than the sternum of moorhen (4.2 cm), pigeon (6.73 cm), crow (6.02 cm) and owl (4.69 cm) and Brown wood owl (5.6 cm). In domestic fowl, the length of the sternum was 15 cm (Sumena and Lucy, 2015). The width of the sternum was maximum at the level of facets (3.27 ± 0.051 cm) followed by caudal extremity (1.42 ± 0.09 cm), and least in the middle (0.85 ± 0.048 cm). In domestic fowl, the width of the sternum was 3 cm (Sumena and Lucy, 2015). Sunilkumar *et al.* (2019) also reported the maximum width of the sternum at the cranial part (2.65 ± 0.11 cm) in the crow. The width of the sternum ranged between 24 and 65 mm in flying birds (Duzler *et al.*, 2006). A wide sternum would produce an attractive appearance for a fighting cock (Kudo *et al.*, 2017).

The cranio-lateral processes (right 2.76 ± 0.037 cm and left 2.64 ± 0.031 cm) were shortest, followed by caudo-dorsal processes (right 3.65 ± 0.06 cm and left 3.43 ± 0.078 cm). Caudo-ventral processes were the longest (right 7.55 ± 0.032 cm and left 7.55 ± 0.132 cm). Caudo-lateral processes of the crow were 1.31 ± 0.06 cm long (Sunilkumar *et al.*, 2019).

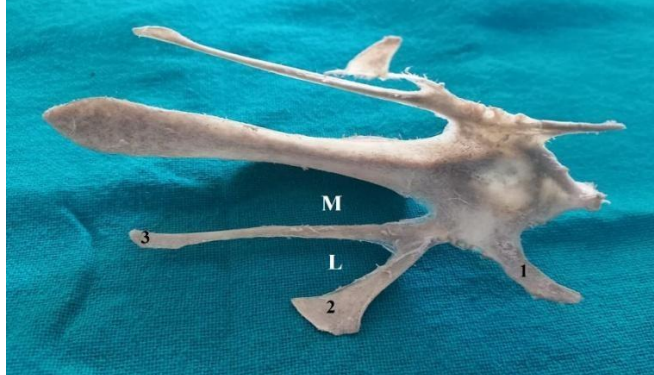



Length of keel at its attached border was 9.47 ± 0.068 cm, whereas the curved length of keel was 11.41 ± 0.095 cm, which was greater than in pigeon (7.15 ± 0.04 cm), crow (5.54 ± 0.03 cm) and owl (4.81 ± 0.03 cm). The height of the keel was maximum at its apex (3.49 ± 0.033 cm).

The distance between the rostrum and right and left cranio-lateral processes was 2.27 ± 0.058 cm and 2.13 ± 0.041 cm, respectively. Distance between right and left cranio-lateral process (A) was 4.49 ± 0.048 cm. This distance was 3.7 ± 0.04 cm in pigeon, 3.38 ± 0.04 cm in crow and 3.57 ± 0.03 cm in owl (John *et al.*, 2014b). The distance between the mid-point of the cranial border of the sternum and the apex of the keel (B) was 4.88 ± 0.015 cm. Average A/B value was 0.92 ± 0.009 . Duzler *et al.* (2006) recorded this value as 1.56 to 1.95 mm in the swimming group, 0.96 to 1.35 mm in the flying group and 0.50 to 0.68 mm in the walking group. The distance between the lateral ends of two articular coracoid grooves (C) was 2.78 ± 0.08 cm. The same was 1.83 ± 0.04 cm in pigeon, 1.22 ± 0.03 cm in crow and 1.4 ± 0.01 cm in owl (John *et al.*, 2014b). The average C/B value was 0.57 ± 0.015 . They also recorded this value as 1.21 to 1.43 mm in the swimming group, 0.63 to 1.04 mm in the flying group and 0.41 to 0.50 mm in the walking group.

References

- Altshuler, D.L., J.W.Bahlman, R.Dakin, A.H.Gaede, B.Goller, D.Lentink, P.S.Segre and D.A.Skandalis (2015), The biophysics of bird flight: functional relationships integrate aerodynamics, morphology, kinematics, muscles and sensors, *Can. J. Zoo.*, **93**: 961-975.
- Bezuidenhout, A.J. (1999), *Anatomy*. In D. C. Deeming (ed.), *The ostrich, biology, production and health*. Oxford: CABI Publishing. pp. 13-51.
- Choudhary, O.P., S.Debroy, Keneisenuo, P.C.Kalita, P.J.Doley, A.Kalita, T.K.Rajkhowa and R.S.Arya (2018), Gross anatomical studies on the sternum of Brown Wood owl (*Strixleptogrammica*), *Ind. J. Vet. Anat.*, **30**(2): 139-140.
- Dursun, N., A.Duzler, E.U.Bozkurt and O.Ozgel (2002), Macroanatomical investigation on sternum in bald ibis (*Geronticuseremita*), *Ind. Vet. J.*, **79**: 160-165.
- Duzler, A., O.Ozgel and N.Dursun (2006), Morphometric analysis of the sternum in avian species, *Turk. J. Vet. Anim. Sci.*, **30**: 311-314.
- Dyce, K.M., W.O.Sack and C.S.G.Wensing (2010), *Veterinary Anatomy*, 4thedn., W.B. Saunders Company, Philadelphia, pp 806-811.
- Girgiri, I.A., M.K.Malah and I.S.Nuhu (2022), Morphology of the sternum, pectoral girdle and wing of West African Black-crowned crane (*Balearica pavonine pavonina*), *Sahel J. Vet. Sci.*, **19**(4): 10-15.
- Jagapathi, R.P., T.S.Chandrasekhara Rao, M.Shanti Lakshmi and Y.Ravindra Reddy (2007), Gross anatomical studies on the sternum and ribs of emu (*Dromaius novaehollandiae*), *Ind. J. Poult. Sci.*, **42**: 112-114.
- Jayachitra, S., K.Balasundaram and S.Paramasivan (2015), Comparative gross anatomical studies on the sternum of emu, turkey and duck, *J. Ani. Res.*, **5**(2): 385-387.
- John, M.A., C.S.Mamde, O.K.Baba and R.U.Rohankar (2014a), Anatomical studies on sternum of pigeon hawk (*Falco columbarius*), *Ind. J. Poult. Sci.*, **49**(2): 231-233.
- John, M.A., J.S.Sasan, K.Ahmed, M.P.S.Tomar, A.Ahmad and A.Singh (2014b), Morphometry of sternum of pigeon, crow and owl, *Ind. Vet. J.*, **91**(03): 40-41.

- Jones, J.C., E.E.White, S.D.Holladay and J.L.Foster (2023), Anatomy of the sternum and humerus in the domestic chicken (*Gallus domesticus*), *Vet. Rad. & Ultra.*, **64**: 1037-1043.
- King, A.S. and J.McLelland (1985), *Form and function in birds*. Volume 3, Academic Press, London.
- Konig, H.E., R.Korbel and H.G.Liebich (2016), *Avian Anatomy: Textbook and Color Atlas*, 2nd edn., 5m Publishing, pp 37-38.
- Kudo, K., N.Tsunekawa, H.Ogawa and H.Endo (2017), Comparative functional morphology of the skeletal forelimb, pectoral girdle and sternum in Japanese native domestic fowls, *J. Poult. Sci.*, **54**: 47-57.
- Pathak, A., S.K.Gupta, A.Verma, M.M.Farooqui, A.Prakash and P.Kumar (2017), Comparative gross anatomy of the sternum in peacock (*Pavo cristatus*), turkey (*Meleagris gallopavo*), duck (*Anas platyrhynchos*) and white-breasted waterhen (*Amaurornis phoenicurus*), *J. Ani. Res.*, **7**(3): 501-505.
- Raghavan, D. (1964), *Anatomy of ox*, Indian Council of Agricultural Research, New Delhi, pp. 17.
- Sasan, J.S., S.Suri and K.Sarma (2023), Histomorphometrical and histochemical studies on the glandular stomach (proventriculus) of Poonchi bird of Union Territory of Jammu and Kashmir, *AATCC Review*, **11**(2), 246-251.
- Sathyamoorthy, O.R., M.Palanivelrajan, S.Ushakumary and C.Sreekumar (2021), Gross morphological and morphometrical studies on the sternum of Asian koel (*Eudynamis scolopacea*), *Ind. J. Ani. Res.*, **55**(5): 550-552.
- Sathyamoorthy, O.R. and G.Ramesh (2006), Gross anatomical studies on the sternum of the ostrich (*Struthio camelus*), *Ind. J. Ani. Health*, **45**: 83-86.
- Sreeranjini, A.R., N.Ashok, V.R.Indu, K.M.Lucy, S.Maya and J.J.Chungath (2015), Gross anatomical features of the sternum of green-winged macaw (*Ara chloroptera*), *Ind. J. Ani. Res.*, **49**:860-862.
- Sumena, K.B. and K.M.Lucy (2015), Comparative studies on keel bones of black drongo, domestic fowl and duck, Proceedings of 7th Kerala Veterinary Science Congress, ISSN 2394-255X, 461-463.
- Sunilkumar, N.S., K.B.Sumena, S.Maya, N.Ashok, K.M.Lucy, V.R.Indu and A.R.Sreerajini (2019), Gross anatomical studies on the sternum of crow (*Corvus splendens*), *Inter. J. Vet. Sci. & Ani. Hus.*, **4**(2): 34-35.
- Tomar, M.P.S., R.Vaish, M.L.Parmar, A.B.Shrivastav and Y.Tiwari (2011), Gross morphometrical studies of sternum of pariah kite (*Milvus migrans*), *Vet. World*, **4**:171-172.
- Wani, S.A., S.K.Pathak, M.A.John, K.Ahmad, F.A.Shiekh and S.Ishaque (2017), Gross morphological studies on sternum of common moorhen (*Gallinula chloropus*), *Int. J. Curr. Micro. and App. Sci.*, **6**(6): 1489-1492.
- Wani, S.A., D.Saran and S.Ishaque (2018), Gross anatomical studies on the sternum of house crow (*Corvus splendens*), *Ind. J. Vet. Ana.*, **30**(2): 143-144.
- Yasuda, M. (2002), *The anatomical atlas of Gallus*, University of Tokyo Press, Tokyo.

	<p>Fig. 1: Dorsal view of sternum showing cranio-lateral process (1), dorsal (2) and ventral (3) divisions of caudo-lateral process, medial incisure (M), lateral incisure (L)</p>
	<p>Fig. 2: Cranial aspect of sternum (dorsal view) showing lateral pneumatic foramen (arrowhead) and facets for sternal ribs (arrow)</p>
	<p>Fig. 3: Cranial view of sternum showing elongated grooves (E) for coracoid bone separated by rostrum (*)</p>
	<p>Fig. 4: Lateral view of sternum showing keel (K) and rostrum (R)</p>