

Morphopathological Evaluation of Cortical Fibrosis and Extra-Renal Changes in Dogs with Chronic Kidney Disease

Pamu Sushma*, Hamza Palekkodan, M.Pradeep, Chintu Ravishankar, Ajith Jacob George, R.Anoopraj, K.Krithiga, Pooja Kailas and Priya Dharshini

Dept. of Veterinary Pathology, College of Veterinary & Animal Sciences, KVASU, Pookode - 673 572

Email: sushmapamu1999@gmail.com

Received: December 2025

25/25

Accepted: February 2026

ABSTRACT

Chronic kidney disease (CKD) is a fatal disease in dogs characterized by progressive nephron loss. Cortical fibrosis serves as a key indicator of renal dysfunction. Although frequently observed, the literature on a systematic study of histological scoring of cortical fibrosis and associated extra-renal lesions in dogs is scarce. The present study screened the kidneys of 50 dog carcasses for gross and histologic changes of cortical fibrosis, along with the associated changes in liver and heart. The kidneys with cortical fibrosis were quantified using ImageJ software in picosirius red-stained sections. Hepatic and cardiac tissues were examined histologically. The study revealed gross and histological lesions of cortical fibrosis in 15 dogs (30 %). On scoring, moderate cortical fibrosis was observed in 93.3 % (n=14) dogs, and marked fibrosis in 6.7 % (n=1) dog. Fibrosis severity was not influenced by age, sex, or breed. Four dogs (26.6 %) had cardiac lesions, mainly cardiomyocyte hypertrophy and arteriosclerosis. Combined cardiac and hepatic lesions, like mild peri-portal fibrosis and hepatic vacuolations, were observed in 5 cases (33.3 %) of moderate cortical fibrosis. The marked cortical fibrosis case also showed combined lesions (6.6 %) of other organs. Statistically, no significant correlation was observed across age, gender and breed-wise occurrence of CKD. The study revealed a higher occurrence of chronic kidney disease in dogs with a comparatively greater association with cardiac lesions.

Keywords: Chronic kidney disease in dogs, Cortical kidney fibrosis, Cardiac and hepatic lesions

INTRODUCTION

Chronic kidney disease is a common and progressive disorder in dogs, characterized by irreversible loss of functional nephrons and compensatory structural remodelling within the renal parenchyma (Perini-Perera *et al.*, 2021). Among the changes, tubulointerstitial fibrosis represents the most consistent histopathological hallmark and a major determinant of renal function decline (Yabuki *et al.*, 2010). The renal cortex contains the highest density of glomeruli and proximal tubules; therefore, cortical fibrosis directly compromises these filtration-critical structures, leading to measurable reductions in GFR. In contrast, medullary fibrosis exerts a comparatively lesser functional impact, as the medulla is primarily involved in urine concentration rather than glomerular filtration (Berchtold *et al.*, 2020). Quantifying cortical fibrosis is therefore essential for assessing disease severity, staging CKD progression, and correlating microscopic alterations with clinical outcomes (Queiroz *et al.*, 2025).

Canine CKD exhibits a multifactorial aetiology, with age, breed, sex, metabolic disturbances, hypertension, and environmental factors contributing to renal damage. However, the degree to which these factors influence cortical fibrotic severity remains unclear (Dunaevich *et al.*, 2020). Additionally, CKD exerts significant systemic effects, leading to secondary pathological changes in extra-renal organs such as the liver and heart, largely due to uremic toxin accumulation, oxidative stress, circulatory disturbances, and activation of the renin-angiotensin-aldosterone system

(Chen *et al.*, 2025). Sensitive staining techniques, such as picosirius red, allow objective quantification of renal fibrosis (Sánchez *et al.*, 2022). Despite their diagnostic value, data regarding the distribution of fibrosis, its association with demographic variables and concurrent lesions in vital organs of CKD-affected dogs remain limited in the Indian context. The present study aims to deliver a comprehensive pathological evaluation of CKD in dogs by assessing renal cortical fibrosis and related systemic alterations.

MATERIALS AND METHODS

Fifty dog carcasses brought for post-mortem at the Department of Veterinary Pathology, College of Veterinary and Animal Science, between June 2024 and August 2025, formed the material for the study. The study population comprised 50 canine cases, consisting of 27 males and 23 females. The animals were categorized into four age groups: 0–2 years (17 dogs), 3–5 years (22 dogs), 6–8 years (8 dogs) and above 9 years (3 dogs). The sample included 17 non-descript dogs, along with several recognized breeds: Labrador Retrievers (8), Pomeranians (6), German Shepherds (5), Huskies (1), Dachshunds (4), Rottweilers (6) and Cane Corso (1), Boxer (2). Gross lesions were recorded, and samples for histopathology were fixed in 10 % neutral buffered formalin. The tissues were processed, sectioned at 4-micron thickness and stained using haematoxylin and eosin stain. The kidneys with gross and histological characteristics of cortical fibrosis were stained with picosirius red stain, and the cortical fibrosis was quantified using ImageJ software (Moon *et al.*, 2022). The scoring was based on the percentage of cortical area affected: normal (0%), mild ($\leq 25\%$), moderate (26–50%) and marked ($>50\%$). Histopathological changes in the liver and heart were examined, and the lesions in these organs were compared with the degree of cortical fibrosis for each case. The association between the age-wise,

gender wise and breed-wise occurrence of CKD in dogs were assessed using two-way ANOVA. All the statistical analyses were performed using GraphPad Prism® 8.0.2 version.

RESULTS AND DISCUSSION

The study revealed cortical fibrosis in 15 cases (30%). The occurrence of cortical fibrosis among the age groups was most frequent in the age group of nine years and above (66 %, n=2), while the lowest was noticed in the 3-5-year group (22.7%, n=5). This pattern alien with the earlier studies reporting greater CKD prevalence in older dogs of age 7 and above and relatively low occurrence in animals younger than four years (Reddy *et al.*, 2021). Males showed a higher (39.20 %) occurrence than the females (18.10 %) and is in accordance with the Perini-Perera *et al.* (2021). The breed-wise data showed a higher occurrence in Husky and Cane Corso (n=1, 100 % each), while the lowest was in Labrador Retriever (12.5 % n=8).

Gross and Histopathological Lesions of Kidneys with CKD

Gross evaluation of the kidneys from the 15 dogs revealed cortical pitting (Plate 1) as the most frequent (26.6%, n= 4) characteristic gross lesion of the CKD. Capsular adhesion in 6.6% (n=1) cases and cortical pitting combined with fibrotic scars was identified in 13.3% (n=2) cases (Plate 2). Numerous necrotic white spots were noted in 2 cases (13.3%). A combined gross lesion of capsular adhesion, fibrotic scarring, and white infarcts; capsular adhesion and cortical pitting; capsular adhesion and haemorrhages; haemorrhages and necrotic foci; capsular adhesion, necrotic foci and congestion; and congestion alone was recorded in a single case each (6.6%). Kidneys with marked pitting, adhesions, or evidence of healed infarction generally showed increased collagen deposition and interstitial fibrosis on histopathology (Alves *et al.*, 2019). In contrast, kidneys with only mild surface irregularities still demonstrated moderate fibrosis,

suggesting that early fibrotic changes may not be readily appreciable on gross examination. This was supported by Tampe *et al.* (2021), as experimental models showed chronic damage leading to focal interstitial fibrosis/tubular atrophy visible as scar, while tubulointerstitial injury produces diffuse fibrosis without prominent gross changes. Overall, gross evaluation provided a preliminary assessment of chronic renal damage, whereas histopathology, particularly picosirius red staining, offered a more accurate and quantitative measure of cortical fibrosis.

Assessment of Cortical Fibrosis in Kidney

Cortical fibrosis was quantified in picosirius red-stained renal sections. Among the 15 canine kidneys examined, 93.3% (n=14) cases exhibited moderate fibrosis (Plate 3), with collagen deposition ranging from 32% to 50 % of the cortical area. Marked fibrosis (Plate 4) with 70% of fibrosis was observed in 6.7% (n=1), reflecting advanced CKD with extensive parenchymal replacement and architectural disruption. Details of the cortical fibrosis in different cases are shown in Fig 1. These results aligned with earlier studies that have shown a correlation between severe interstitial fibrosis and progressive renal dysfunction leading to poor clinical outcomes in dogs (Yhee *et al.*, 2010; Street *et al.*, 2014; Perini-Perera *et al.*, 2021).

Hepatic Lesions Associated with CKD

Microscopic examination of the liver in dogs with cortical fibrosis revealed mild portal fibrosis (Plate 5) that may cause chronic metabolic acidosis and nitrogenous waste accumulation, further contributing to periportal fibrotic responses (Brunetto *et al.*, 2021). Vacuolar degeneration of hepatocytes with peripheral nuclear displacement (Plate 6) indicates impaired lipid transport and mitochondrial dysfunction, paralleling findings reported in human studies of CKD-associated hepatic alterations (Marc *et al.*, 2022; Seo *et al.*, 2022). Hepatic cord architecture was disrupted, accompanied by

sinusoidal congestion and dilatation (Plate 7) that could be caused by the venous outflow impairment (Kakar *et al.*, 2004). Overall, these hepatic changes illustrate the multifactorial impact of chronic renal insufficiency, highlighting the systemic consequences of CKD on hepatic morphology and function, including metabolic, oxidative and vascular mechanisms.

Cardiac Lesions Associated with CKD



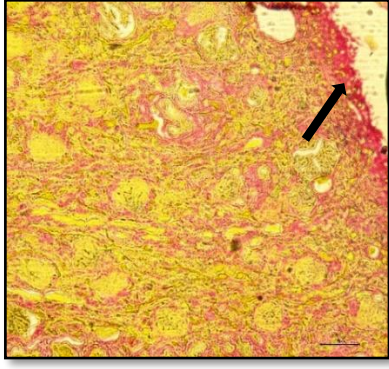
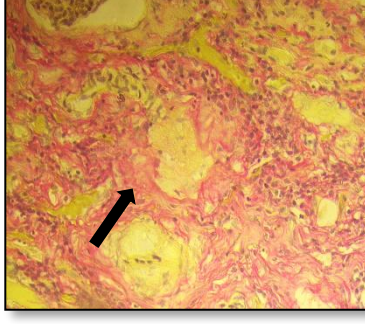
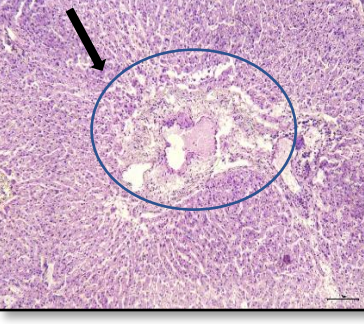
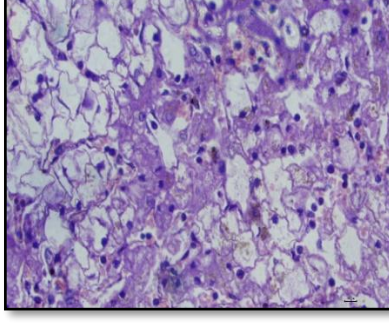
Microscopic examination of the heart in dogs with cortical fibrosis revealed hypertrophic cardiomyocytes characterized by enlarged myofibers, vesicular nuclei and prominent nucleoli, consistent with concentric hypertrophy (Plate 8). These are indicative of chronic systemic hypertension and renin-angiotensin-aldosterone system activation, both of which are central components of cardiorenal axis dysfunction (Pouchelon *et al.*, 2015; Ames *et al.*, 2019). Concurrent vascular lesions of arteriosclerosis with thickened arterial walls and narrowed lumina (Plate 9) were observed, contributing to impaired myocardial perfusion, ischemic stress, and interstitial fibrosis. The combination of these two lesions reflects sustained hemodynamic overload and neurohormonal stimulation associated with CKD. Similar cardiac remodelling patterns marked by progressive hypertrophy, reduced myocardial compliance, and evolving diastolic dysfunction have been documented in canine cardiorenal disorders (Flora *et al.*, 2025). Overall, these findings highlight the significant impact of chronic renal insufficiency on cardiac structure and function, emphasizing the integrated pathology of the cardiorenal axis.

Concurrent Affection of Liver and Heart

Concurrent affections of both liver and heart were identified in 5 cases (33.3%) of moderate and marked cortical fibrosis. The heart alone was found to be affected in 4 cases (26.6%) where arteriosclerosis was evident. Arteriosclerosis in the heart vessels may develop secondary to kidney disease,

contributing to cardiac dysfunction (Martinelli *et al.*, 2016). Lesions in the liver without the affections of the heart were not observed in any of the cases. Overall, the findings suggested that the occurrence of cardiac lesions is higher compared to hepatic lesions in dogs with renal cortical fibrosis. Chortara *et al.* (2025) reported that the prevalence of heart disease increased in more advanced stages of CKD, and liver comorbidities appear to be 15 to 17 % in CKD. Sant Anna *et al.* (2019) opined that the liver lesions were less frequently reported as a direct consequence of CKD in dogs, and the liver pathology was often linked to

concurrent systemic or infectious diseases rather than primary CKD-driven fibrosis. In the present study, an increase in the severity of cortical fibrosis appeared to be associated with the involvement of both liver and heart. Notably, the single case with marked fibrosis observed in the present study exhibited lesions in both heart and liver, supporting the possibility that severe renal fibrosis may accompany more widespread systemic pathology. This underscores the importance of monitoring both renal fibrosis for CKD staging and cardiac health for potential secondary involvement in canine CKD management.

| | | |
|---|--|---|
|  |  |  |
| <p>Plate 1. Kidney: White focal spots alongside cortical pitting observed in the kidney (arrow)</p> | <p>Plate 2. Kidney: The left kidney shows a well-defined area of cortical scarring (arrow), while the right kidney demonstrates pitting (arrow)</p> | <p>Plate 3: Kidney: cortical area showing moderate fibrosis (red colour) (Sirius red, x 100) (arrow)</p> |
|  |  |  |
| <p>Plate 4: Kidney: cortical area showing marked fibrosis (red colour) (Sirius red, x 400) (arrow)</p> | <p>Plate 5: Liver: mild periportal fibrosis (H and E, x100)</p> | <p>Plate 6: Liver: hepatocytes with numerous fat vacuoles of varying sizes and distortion of hepatic cell architecture (H and E, x400)</p> |

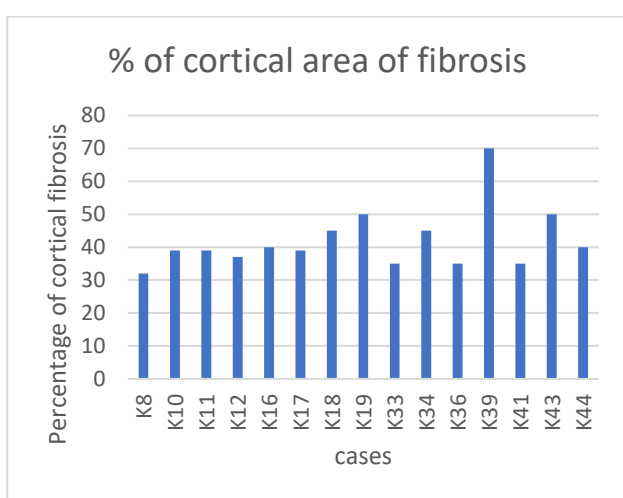
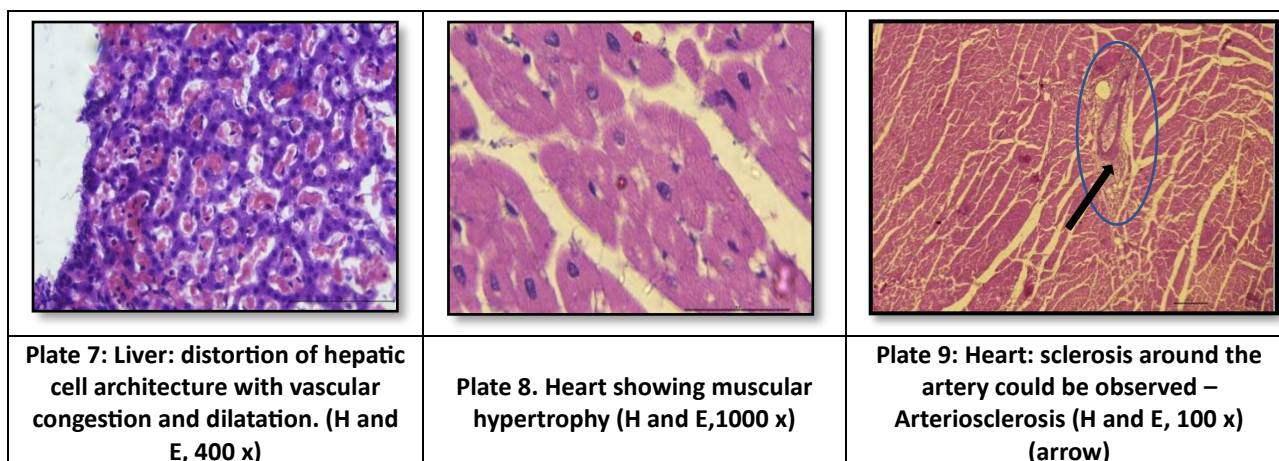


Figure 1: Total cortical fibrosis scoring in picrosirius red-stained kidney sections

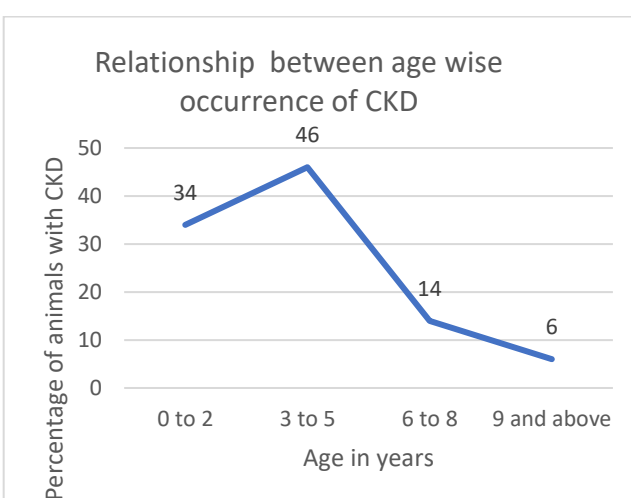


Figure 2: Relationship between age wise occurrence of CKD

Statistical Analysis

No statistically significant correlation was found for age-wise occurrence (row factor: $F(1,3)=0.5339$, $P=0.5179$; column factor: $F(3,3)=0.5179$, $P=0.9227$), gender-wise occurrence (row factor: $F(1,1)=57.58$, $P=0.0834$; column factor: $F(1,1)=52.92$, $P=0.0870$), or breed-wise occurrence (row factor: $F(1,8)=5.206$, $P=0.0519$; column factor: $F(8,8)=0.7401$, $P=0.6598$) (Fig 2 to 4). In contrast, Tarrant *et al.* (2025) reported significant associations with age and gender, while breed showed no significant influence. The lack of significance in the present study may be attributed to the relatively small sample size and other comorbidities for CKD.

CONCLUSION

A higher occurrence of CKD was evident in dogs, especially in those above nine years old, but statistical significance was not observed. Sex and breed categories revealed no strong predisposition through statistical analysis, indicating that cortical fibrosis is a universal feature of CKD progression rather than one influenced by demographic factors. The presence of moderate cortical fibrosis without clear gross lesions such as cortical pitting, capsular adhesions, and fibrotic scarring reaffirmed that gross pathology alone underestimates the true extent of renal damage. Quantitative assessment using picrosirius red staining proved essential in accurately characterizing extracellular matrix

expansion and chronic parenchymal injury. Cardiac alterations, including cardiomyocyte hypertrophy and arteriosclerosis, were more frequent than hepatic changes, underscoring the heightened susceptibility of the heart within the cardiorenal axis. The single case with marked fibrosis also exhibited both hepatic and cardiac abnormalities, suggesting that severe renal fibrosis may parallel broader systemic involvement.

Overall, the findings highlight the multifactorial impact of CKD on canine health, emphasizing the value of integrating quantitative fibrosis assessment with systemic pathology. Early detection and grading of renal fibrosis, together with monitoring of cardiac status, are essential for improving clinical management and prognostic evaluation in dogs with CKD.

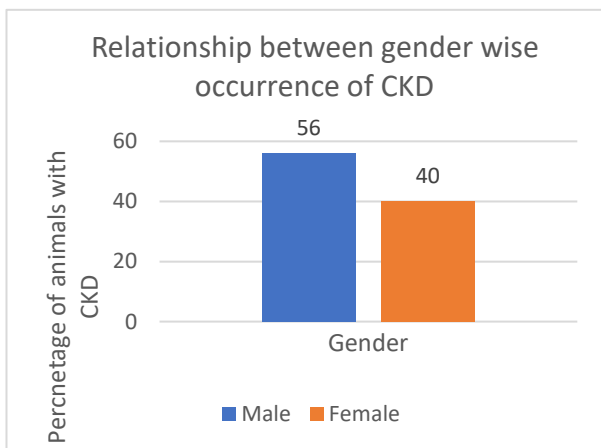


Figure 3: Relationship between gender wise occurrence of CKD

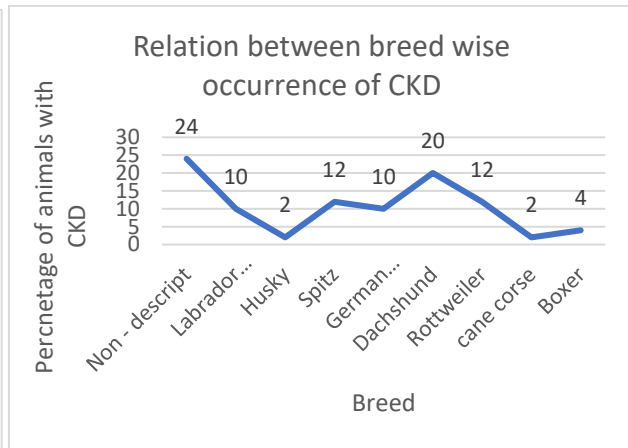


Figure 4: Relationship between breed-wise occurrence of CKD

ACKNOWLEDGEMENT

The authors thank the Kerala Veterinary and Animal Sciences University, Wayanad, for funding this study.

REFERENCES

Alves, A.F., R.A.Pereira, H.M.de Andrade, D.M.Mosser and W.L.Tafari (2019), Immunohistochemical study of renal fibropoiesis associated with dogs naturally and experimentally infected with two different strains of *Leishmania (L.) infantum*, *Int. J. Exp. Pathol.*, **100**(4): 222–33.

Ames, M.K., C.E.Atkins and B.Pitt (2019), The renin-angiotensin-aldosterone system and its suppression. *J. Vet. Intern. Med.*, **33**(2): 363-82.

Berchtold, L., I.Friedli, L.A. Crowe, C.Martinez, S.Moll, K.Hadaya, T.de Perrot, C.Combescure, P.Y.Martin, J.P.Vallée and S.de Seigneux (2020), Validation of the corticomedullary difference in magnetic resonance imaging-derived apparent diffusion coefficient for kidney fibrosis

Brunetto, M.A., B.Ruberti, D.P.Halfen, D.S.Caragelasco, T.H.A.Vendramini, V.Pedrinelli and M.M.Kogika (2021), Healthy and chronic kidney disease (CKD) dogs have differences in serum metabolomics and renal diet may have slowed disease progression, *Metabolites*, **11**(11): 782.

Chen, M.C., C.H.Kuo, Y.L.Lin and B.G.Hsu (2025), Gut-derived uremic toxins and cardiovascular health in chronic kidney disease, *Tzu Chi Med. J.*, **37**(3): 264–74.

Chortara, I., C.N.Tsokana, E.Pavlidou, T.L.Sandri, A.Wright and G.Valiakos (2025), Real-world data on canine chronic kidney disease in Greece: clinical and quality of life insights, *Front. Vet. Sci.*, **12**: 1601044.

Dunaevich, A., H.Chen, D.Musseri, S.Kuzi, M.Mazaki-Tovi, I.Aroch and G.Segev (2020), Acute on chronic kidney disease in dogs: Etiology, clinical and clinicopathologic findings,

- prognostic markers, and survival, *J. Vet. Intern. Med.*, **34**(6): 2507–15.
- Flora, Z., P.K.Tang, K.Smith and J.Elliott (2025), Cardiac pathology associated with hypertension and chronic kidney disease in aged cats, *J. Comp. Pathol.*, **216**: 40-49.
- Ha, S., M.Son, J.Kim, D.Kim, M.J.Kim, J.Yoo and K.W.Chung (2025), Gender Differences in Adenine Diet-Induced Kidney Toxicity: The Impact of 17 β -Estradiol on Renal Inflammation and Fibrosis, *Int. J. Mol. Sci.*, **26**(3): 1358.
- Kakar, S., P.S.Kamath and L.J.Burgart (2004), Sinusoidal dilatation and congestion in liver biopsy: is it always due to venous outflow impairment? *Arch. Pathol. Lab. Med.*, **128**(8): 901-04.
- Marc, L., A.Mihaescu, R.Lupusoru, I.Grosu, F.Gadalean, F.Bob and A.Schiller (2022), Liver steatosis: better predictor of CKD in MAFLD than liver fibrosis as determined by transient elastography with controlled attenuation parameter, *Front. Med.*, **8**: 788881.
- Martinelli, E., C.Locatelli, S.Bassis, S.Crosara, S.Paltrinieri, P.Scarpa, I.Spalla, A.M.Zanaboni, C.Quintavalla and P.Brambilla (2016), Preliminary Investigation of Cardiovascular-Renal Disorders in Dogs with Chronic Mitral Valve Disease, *J. Vet. Intern. Med.*, **30**(5): 1612–18.
- Moon, J.J., Y.Choi, K.H.Kim, A.Seo, S.Kwon, Y.C.Kim and S.H.Yang (2022), Inhibiting transglutaminase 2 mediates kidney fibrosis via anti-apoptosis, *Biomedicines*, **10**(6): 1345.
- Perini-Perera, S., J.Del-Ángel-Caraza, A.P.Pérez-Sánchez, I.A.Quijano-Hernández and S.Recillas-Morales (2021), Evaluation of chronic kidney disease progression in dogs with therapeutic management of risk factors, *Front. Vet. Sci.*, **8**: 621084.
- Pouchelon, J.L., C.E.Atkins, C.Bussadori, M.A.Oyama, S.L.Vaden, J.D.Bonagura and N.Van Israël (2015), Cardiovascular–renal axis disorders in the domestic dog and cat: a veterinary consensus statement, *J. Small Anim. Pract.*, **56**(9): 537-52.
- Queiroz, L.C.S., A.A.V.C.Bulhes, D.D.Caus, F.L.G.Marques, F.C.Costa, L.T.Ramos, G.Soaes, S.N.do, D.C.M.Mota, I.S.Borges, M.V.V.Silva, V.S.F.Santos and J.C.T.Santos (2025), Histopathological comparison of renal interstitial lesions in dogs with chronic kidney disease of different stages, *Inter. Seven Multidisciplinary J.*, **4**(2): 273-79.
- Reddy, A.K., K.Lakshmi, G.Ambica and B.A.Kumar (2021), Incidence of chronic kidney disease in dogs, *The Pharma Innovation J.*, **10**(7): 738–44.
- Sánchez-Jaramillo, E.A., L.E.Gasca-Lozano, J.M.Vera-Cruz, L.D.Hernández-Ortega and A.M.Salazar-Montes (2022), Automated Computer-Assisted Image Analysis for the Fast Quantification of Kidney Fibrosis, *Biology*, **11**(8): 1227.
- Sant'Anna, R., A.S.Vieira, J.Oliveira and W.Lilenbaum (2019), Asymptomatic leptospiral infection is associated with canine chronic kidney disease, *Comp. Immunol. Microbiol. Infect. Dis.*, **62**: 64-67.
- Seo, D.H., Y.J.Suh, Y.Cho, S.H.Ahn, S.Seo, S.Hong and S.H.Kim (2022), Advanced liver fibrosis is associated with chronic kidney disease in patients with type 2 diabetes mellitus and nonalcoholic fatty liver disease, *Diabetes Metab. J.*, **46**(4): 630-39.
- Street, J.M., A.C.Souza, A.Alvarez-Prats, T.Horino, X.Hu, P.S.Yuen and R.A.Star (2014), Automated quantification of renal fibrosis with Sirius Red and polarization contrast microscopy, *Physiol. Rep.*, **2**(7): e12088.
- Tampe, D., L.Schridde, P.Korsten, P.Ströbel, M.Zeisberg, S.Hakrrouch and B.Tampe (2021), Different Patterns of Kidney Fibrosis Are Indicative of Injury to Distinct Renal Compartments, *Cells*, **10**(8): 2014.
- Tarrant, G., L.Boyden, T.Rai, A.Wright, A.J.Cook and K.Wells (2025), Gaining insights into pet owner understanding/lived experience of canine chronic kidney disease using survey and social media data, *Frontiers. Vet. Sci.*, **12**:1506272.
- Yabuki, A., S.Mitani, M.Fujiki, K.Misumi, Y.Endo, N.Miyoshi and O.Yamato (2010), Comparative study of chronic kidney disease in dogs and cats: Induction of myofibroblasts, *Res. Vet. Sci.*, **88**(2): 294–99.
- Yhee, J.Y., C.H.Yu, J.H.Kim, K.S.Im, S.K.Chon and J.H.Sur (2010), Histopathological retrospective study of canine renal disease in Korea, 2003~2008, *J. Vet. Sci.*, **11**(4): 277.